

Effects of Combined Robotic Therapy and Repetitive-Task Practice on Upper-Extremity Function in a Patient With Chronic Stroke

Libby Rosenstein, Angela L. Ridgel, Anil Thota, Bridgette Samame, Jay L. Alberts

KEY WORDS

- assistive technology
- occupational therapy
- robotics
- stroke
- upper extremity
- wrist movement

OBJECTIVE. This article describes the effect of a robotic device combined with repetitive-task practice (RTP) on upper-extremity function in a patient with chronic stroke.

METHOD. The client was a 32-year-old woman, 11 months after stroke, with minimal wrist and finger movement. She received approximately 48 hr of intervention split evenly between a robotic device (Hand Mentor) and RTP during 3 weeks.

RESULTS. Favorable scores in the Wolf Motor Function Test were observed from pre- to postevaluation. Active range of motion, from pre- to postintervention, increased by 35° in the shoulder, 65° in the wrist, and 70° in the thumb. Kinetic analysis of a bimanual dexterity task indicated improved specification of grasping forces for both limbs.

CONCLUSION. Improvements in upper-extremity motor functioning and functional performance in daily tasks followed this client's engagement in distal initiation of movement during an RTP exercise regimen that was robotically reinforced.

Rosenstein, L., Ridgel, A. L., Thota, A., Samame, B., & Alberts, J. L. (2008). The effects of combined robotic therapy and repetitive-task practice on upper-extremity function in a patient with chronic stroke. *American Journal of Occupational Therapy*, 62, 28–35.

Libby Rosenstein, OTR/L, is Occupational Therapist, Clinical Specialist, Department of Occupational Therapy, Cleveland Clinic, Cleveland, OH 44195; rosensl@ccf.org

Angela L. Ridgel, PhD, is Postdoctoral Research Fellow, Department of Biomedical Engineering, Cleveland Clinic, Cleveland, OH.

Anil Thota, MS, is Research Engineer, Department of Biomedical Engineering, Cleveland Clinic, Cleveland, OH.

Bridgette Samame, OTR/L, is Occupational Therapist, Department of Occupational Therapy, Cleveland Clinic, Cleveland, OH.

Jay L. Alberts, PhD, is Investigator, Department of Biomedical Engineering and Center for Neurological Restoration, Cleveland Clinic; and Investigator, Louis Stokes Veterans Affairs Medical Center, Cleveland, OH.

It has been estimated that 30% to 66% of stroke survivors are unable to functionally use the affected upper extremity for activities of daily living (ADLs) after therapy (van der Lee et al., 1999). Patients with hemiparesis following stroke typically exhibit a decrease in muscle strength and coordination along with changes in tone. When patients with increased flexor tone or stiffness attempt to use the more affected hand, a common pattern is increased wrist flexion, which then weakens grip strength by means of passive forces on the extensors (Johanson & Murray, 2002). Previous studies have reported that 35° of wrist extension is the optimal position to achieve maximal grip strength, and maximum force is decreased by approximately 75% when wrist extension is limited to 15° (O'Driscoll et al., 1992).

In a systematic review of 151 studies, there was insufficient evidence that traditional neurological treatment methods (e.g., Bobath, Proprioceptive Neuromuscular Facilitation, Brunnstrom) were effective in improving muscle strength, synergies, muscle tone, dexterity, or ADLs after stroke (Van Peppen et al., 2004). Although strengthening was effective in lower extremity treatment, strengthening the upper extremity did not lead to changes in control and coordination of digit forces. In a study of patients with acute stroke (Winstein et al., 2004), strengthening and task-specific functional training were effective primarily with higher-level patients.

Specific changes in fine motor function were not noted. Our recent kinetic data indicated that changes in maximum strength were not predictive of manual function (Alberts, Butler, & Wolf, 2004). Only interventions that incorporated functional task-oriented training, such as constraint-induced therapy (CIT; Wolf et al., 2006) and bilateral arm training, have led to improvements in dexterity (Van Peppen et al., 2004).

The CIT intervention, which uses repetitive and adaptive task practice, has been shown to be effective toward recovering upper-extremity function (Alberts et al., 2004; Wolf, Blanton, Baer, Breshears, & Butler, 2002). In CIT programs, patients received 6 hr per day of treatment and wore a mitt for 90% of their waking hours. Although CIT is very effective in improving upper-extremity function, several obstacles hinder its implementation in a clinical environment. A review by Levine and Page (2004) found that more than 70% of stroke patients did not want to participate in traditional CIT programs because of concerns about decreased independence with daily tasks and program costs. Moreover, approximately 70% of therapists said their facilities did not have adequate personnel or resources to perform CIT.

Robotics is an area of interest in stroke rehabilitation that may be beneficial for the patient while increasing staff productivity. Several studies have reported improvements in strength and motor function with robotic treatment (Burgar, Lum, Shor, & Machiel Van der Loos, 2000; Finley et al., 2005). Most robotic interventions, however, support the wrist, and movements are initiated proximally, suggesting that robot-aided therapy using repetitive, targeted activity may improve motor function at the shoulder and elbow.

We are unaware of any published studies that have shown robotic therapy to be effective in improving distal motor function. The purpose of this intervention was to describe the effects of a combined intervention. We used repetitive-task practice (RTP) and an assistive repetitive motion robotic device called the Hand Mentor (HM; Kinetic Muscles Inc., Tempe, AZ) to increase upper-extremity function in a patient with chronic stroke with minimal finger and wrist movement. The HM is focused on improving active range of motion (AROM) in wrist flexion and extension, wrist control, and initiating movement distally. When all movement is initiated proximally, it may result in a synergy pattern with most active movement occurring at the shoulder, leaving the distal portion of the limb with minimal control. When patients are encouraged to focus on initiating and strengthening movements distally (after stabilizing proximally), they may have greater potential for isolating and varying movements. Most upper-extremity

actions are initiated distally; movements begin with finger or wrist motion and are followed by elbow and then shoulder motion (distal to proximal) for use in functional upper-extremity tasks (Saling, Stelmach, Mescheriakov, & Berger, 1996). We predicted that a combined intervention of RTP and HM would lead to functional improvements in upper-extremity motor performance.

Case Description

The patient was a 32-year-old, right-hand-dominant woman, 11 months after a stroke. She had embolic stroke affecting the basal ganglia 5 days after delivering her first child by caesarian section. The patient did not receive tissue plasminogen activator. She received inpatient and outpatient occupational, physical, and speech therapy immediately after the stroke. The patient displayed expressive aphasia, but although she had word-finding problems, she was able to convey her needs. She could communicate through writing (using only her nondominant, unaffected left upper extremity). The patient was able to follow most complex directions.

Before intervention, she did not use her right upper extremity for any functional tasks, not even to assist the left upper extremity. She used only her nondominant left upper extremity for all self-care, home management, and child care tasks. She did not need assistance for self-care and was able to perform light homemaking tasks, but she needed assistance with child care. When writing with her left hand, she did not attempt to stabilize the paper with her right hand. All movement was initiated at the shoulder. She was able to move only in a synergy pattern by abducting and internally rotating the shoulder and flexing the elbow and wrist. When attempting to reach for objects, she was able to extend her elbow no more than -75° . She was able to extend her wrist approximately -25° on one concentrated attempt. She otherwise was unable to extend the wrist from full flexion. A high degree of tenodesis of the fingers was present at the preintervention evaluation. Therefore, when she attempted to extend her wrist, the fingers tightly flexed. Only when the patient flexed her wrist was she able to extend the fingers approximately half range. With the wrist supported in neutral, her metacarpal-phalangeal extension of the index and small fingers ranged from -60° to -35° . She was unable to isolate finger movements. Thumb carpal-metacarpal abduction was positioned at -20° , with no active movement. On the Modified Ashworth Scale (Gregson et al., 1999), she scored 1+ for the wrist flexors. This patient would be considered too low functioning to be included in a CIT intervention according to the inclusion criteria of the EXCITE trial (Wolf et al., 2005).

Methods

A separate blinded evaluator performed pre- and postintervention movement evaluations. Evaluations and intervention were done by occupational therapists. Each day, the patient started with 2 hr using the HM and 2 hr of RTP (including one to two 10- to 15-min breaks per day). The patient completed 12 of the 15 scheduled days, missing 3 days because of illness. The patient provided informed consent before evaluations and intervention. During this intervention, she was receiving no other therapy services.

The HM (Figure 1) uses a pneumatic artificial muscle (McKibben muscle) and provides biofeedback regarding muscle activation and control. The purpose of the HM is to inhibit flexor tone of the fingers and wrist, to provide neuro-reeducation, and to increase range of motion (ROM) and strength of the fingers and wrist. The HM has three treatment-focused antispasticity modes of varying duration. In the antispasticity modes, the HM passively places the wrist in different angles of extension. The patient is then required to hold that position. If the patient begins flexing the wrist, several light-emitting diodes (LEDs) appear as negative feedback. If the patient decreases force, the LEDs disappear. The patient is required to hold each position for 30, 60, or 90 s, depending on the mode. Sensitivity can be gradually changed by the therapist to a total of six increments. Higher sensitivity values correspond to easier task requirements.

Two motor control modes—up and down—encourage active wrist extension and flexion. In the Motor Control Down mode, the patient actively flexes the wrist and, after reaching full range, extends the wrist while the LEDs provide wrist position feedback. Sensitivity is set for low resistance to minimize use of flexor tone during wrist flexion. In the Motor Control Up mode, the patient extends the wrist to increase the number of LEDs illuminated on the panel. The motor unit recruitment mode uses surface electromyography

to encourage greater wrist extension. The amount of extensor activity is represented by the number of LEDs illuminated. Even if the patient is unable to extend the wrist, extensor activity may be detected and displayed on the LED panel. In the motor control and EMG modes, the pneumatic muscle will inflate and actively assist the movement if the patient is unable to obtain the target position.

RTP is massed practice in which the patient performs functional activities repetitively for at least 15 to 30 min. It may be a complete activity or focus on components of movement, eventually combining the components. Only the more affected upper extremity is used to perform the tasks. These activities are gradually increased in difficulty, and the selected activities are chosen by the patient (Wolf et al., 2002).

Using RTP, the difficulty of the task was gradually increased with requirements for increased accuracy and decreased time. The Flinn Performance Screening Tool (Flinn & Ventura, 1997) was used to identify meaningful tasks for the patient using large, lifelike pictures of self-care, home, work, and leisure tasks. The patient pointed to the activities she wanted to practice. Most of the tasks incorporated use of the trunk and the entire upper extremity, although focus was primarily on stabilization of the scapula and distal initiation of movement. Tasks included the following: self-feeding (with finger foods and using a spoon and cup), ironing, sweeping with a broom, using the Baltimore Therapeutic Equipment steering wheel, turning faucets on and off, writing, scooping dirt and filling pots with a small hand-held shovel, carrying a laundry basket while climbing stairs, and playing pool. Tasks performed only once and then discontinued because the level was too difficult for the patient were squeezing a sponge and washing the table, picking up large pegs and dropping them to the floor, vacuuming, playing cards, and hanging up shirts.

Outcome measures include the Wolf Motor Function Test (WMFT; Wolf et al., 2001), the upper-extremity portion of the Fugl-Meyer Motor Assessment (FMA; Fugl-Meyer, Jaasko, Leyman, Olsson, & Stegling, 1975), and the Modified Ashworth Scale. The WMFT uses 15 timed tests for a maximum of 120 s on each item; it assesses upper-extremity gross-motor and fine-motor movements relative to functional tasks. Test-retest reliability is .90 or greater for performance time and .95 for functional ability (Morris, Uswatte, Crago, Cook, & Taub, 2001; Wolf et al., 2001). The relationship between WMFT scores shows that this test is valid and consistent with values previously reported (Wolf et al., 2001). The FMA measures motor function in and out of synergy patterns, grasp, coordination, and reflex testing. Scoring ranges from 0 to 2 for all items: 0 = *unable to perform the movement*, 1 = *partially able to perform the movement*, and 2 = *fully able to perform movement*. The maximum score is




Figure 1. Illustration of Hand Mentor (HM) device. The patient was seated and the more affected arm was put in the HM. Visual feedback was provided to the patient on the display screen.

66 for the upper-extremity motor section. FMA has a test-retest reliability of .98, has an interrater reliability of .97, and has been shown to have construct and criterion validity (Morris et al., 2001; Wolf et al. 2001). The Modified Ashworth Scale, which specifically assesses spasticity by means of a quick stretch response, uses a grading scale ranging from 0, indicating no increase of muscle tone, to 5, which indicates rigidity. The assessment has test-retest reliability of .83 and interrater reliability of .84 (Gregson et al., 1999).

Upper-extremity motor function was assessed using two identical force and torque transducers that measure normal (grip), tangential (lifting), shear forces, and their associated torques. This task is modeled after functional object manipulation tasks performed on a daily basis (e.g., grasping a small object and opening a container; Alberts, Tresilian, & Stelmach, 1998; Alberts et al., 2004). The patient was asked to separate the two transducers with a resistance level of 5N (Newtons). This task requires that one limb stabilize the bottom portion of the device while the other manipulates or pulls the upper portion to separate the two objects. Maximum grip and load forces of both the unaffected and the affected hands were calculated for each trial.

Results

The patient used the 60- and the 30-s antispasticity mode of the HM. She learned to control her flexor tone while using these modes. In Motor Control Down mode, the patient initially was able to flex, but not extend, the wrist. She gradually was able to extend to neutral but used synergistic movement in her entire body to do so. By the end of the treatment, she was able to reach the top-goal LED for wrist extension without rotating the forearm and without using synergistic patterns. Before the intervention, the patient was not able to use Motor Control Up mode, in which extension of the wrist increases the number of LEDs illuminated on the panel. By the end of treatment, she was able to perform this task inconsistently, at the lowest level as represented by a high-sensitivity number. She still used some compensatory lateral trunk flexion. In biofeedback modes, the patient was able to initiate isolated wrist movements increasing LED feedback after intervention.

The patient used RTP to perform several functional tasks. During ironing, the patient was initially unable to keep the iron on the board. She flexed the wrist and elbow, which created wobbling of the iron. By the end of the intervention, she was able to use her wrist and elbow in extension to keep the iron on the surface and to use shoulder adduction, abduction, and external rotation to effectively and safely move the hot iron.

Before intervention in self-feeding, movement was initiated proximally, by means of scapular elevation, internal rotation and abduction of the humerus, and elbow flexion. The patient was unable to reach her mouth, even with the right elbow supported on the table. By the last session, she was able to slowly finger and spoon feed, using lateral pinch on a disposable plastic spoon with foam to enlarge the handle. She was able to keep the humerus adducted and her scapula depressed, maintaining her elbow on the table for the task. She could then initiate distal movements, stabilizing the wrist in neutral extension, and control the elbow movements and shoulder rotation.

When sweeping with a broom, she initially used only the left upper extremity to push the broom, passively following with the right. The right wrist was flexed and the hand slid down the broom because of decreased grip force. At the end of the intervention, she kept her wrist in neutral extension and maintained an effective grip on the broom. She used the right upper extremity to push while the left upper extremity stabilized the broom.

When writing before intervention, the patient was unable to make marks on paper, but after the intervention, she could make irregular, fairly legible letters to write her name using a lateral pinch on the Steady Write (Sammons Preston, Bolingbrook, IL) pen. Most of her movement to perform the task was proximal, but she was able to use wrist flexion and extension to form letters.

At the end of intervention, the patient was functionally able to hold her wrist stable in neutral extension during most of the RTP without coaching. With the wrist in neutral or slightly more extension (up to 15°), her grip strength was functional for broom-sized objects, and she still required foam or enlarged handles for smaller items.

The patient displayed improvements in subsections of the WMFT for the following: forearm to table, extend elbow side, reach and retrieve, and lifting a basket (Table 1). She increased weight to box by 2 lb. She did not show changes in the areas requiring grasping items, which she was initially unable to perform, such as lifting a can, pencil, or paper clip, and folding the towel, because of limited finger movement and fine motor control.

On the Fugl-Meyer upper-extremity motor pretest, the patient scored 23/66; on the posttest, she scored 26/66. She had favorable changes in dysmetria and tremor, improving from 1 to 2 points on each item. She scored 1 for finger flexion, 0 for extension, and 0 for the grasps, which did not change after intervention. On the Modified Ashworth Scale, elbow flexor tone reduced from 1+ to 1 after treatment, but forearm and wrist flexors remained unchanged at 1+. Shoulder passive ROM increased in flexion, abduction, external rotation, and internal rotation. Her AROM improved in carpal-

Table 1. Wolf Motor Function Test

Test	Pretest	Posttest	Difference	Change Trajectory
Forearm to table(s)	1.17	1.04	0.13	favorable
Forearm to box(s)	1.59	1.70	0.11	unfavorable
Extend elbow side(s)	11.94	1.99	9.95	favorable
Extend elbow weight(s)	1.88	1.93	.05	unfavorable
Hand to table front(s)	1.84	1.95	0.11	unfavorable
Hand to box front(s)	3.77	4.77	1.00	unfavorable
Reach and retrieve(s)	0.55	0.32	0.23	favorable
Lift can(s)	120 (unable)	120 (unable)	0	no change
Lift pencil(s)	120 (unable)	120 (unable)	0	no change
Lift paper clip(s)	120 (unable)	120 (unable)	0	no change
Stack checkers(s)	120 (unable)	120 (unable)	0	no change
Flip cards(s)	120 (unable)	120 (unable)	0	no change
Turn key in lock(s)	120 (unable)	120 (unable)	0	no change
Fold towel(s)	120 (unable)	120 (unable)	0	no change
Lift basket(s)	120 (unable)	8.00	N/A	favorable
Weight to box (lb)	2	4	+2	favorable
Average grip strength (kg)	13	14	+1	favorable

Note. All items in **bold** represent patient improvement. On timed testing, a decrease in time is desired. A score of 120 indicates that the patient cannot perform the task. Lift basket dramatically improved from unable to perform to performing in 8 s. Extend elbow side showed a decrease of 9.95 s. Small favorable changes were noted in forearm to table and reach and retrieve. Weight to box increased by 2 lb, and grip strength increased by 1 lb. No improvement in tasks requiring grasp-and-release was found. N/A = not available.

metacarpal thumb abduction, wrist extension, forearm supination, and shoulder flexion (Figure 2).

The bimanual dexterity task requires a limb to stabilize the lower portion of the device while the other limb manipulates or pulls on the upper portion (Figure 3A). The patient used her unaffected limb to stabilize, and the affected limb was used to manipulate or pull the object. Before the intervention the patient was unable to separate the two objects.

She had sufficient strength to perform the task (e.g., grip forces were greater than 5 N; Figure 3B). However, she appeared to have difficulty coordinating and synchronizing grasping forces. After the intervention, she was able to perform the task by a sequential method of grasping force activation (e.g., the onset of the grip force in the unaffected hand precedes affected force onset, which is followed by the pulling force; Figure 3C). The force–time component of the

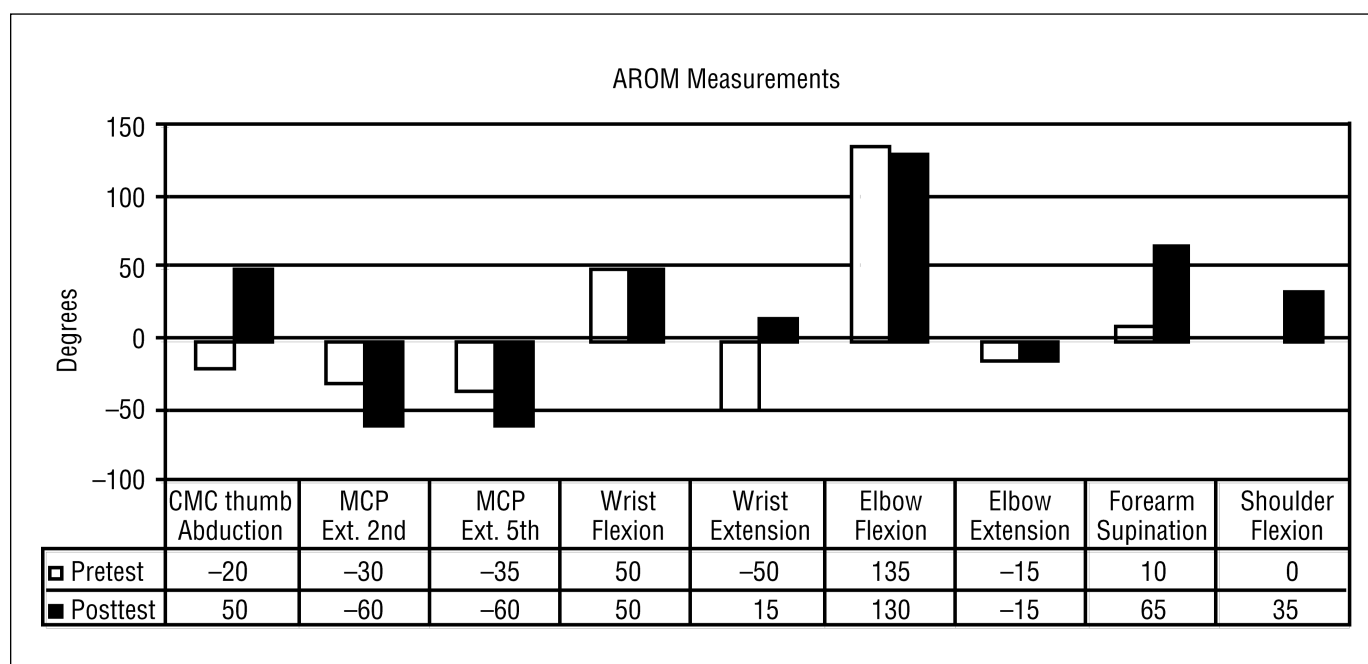


Figure 2. Active range of motion (AROM) measurements before and after repetitive-task practice/Hand Mentor intervention. The patient improved in carpal–metacarpal (CMC) thumb abduction, wrist extension, forearm supination, and shoulder flexion. MCP = metacarpal–phalangeal.

forces improved, and grip and pulling forces were smoother with fewer peaks in the postintervention compared with preintervention session.

Discussion

After a stroke, patients who exhibit minimal finger and thumb movement, as well as increased tone, have significant barriers to rehabilitation. Using a robotic device as an adjunct to other treatment strategies may allow lower-functioning patients to increase their AROM. The combined use of RTP and HM was effective for gaining functional movement of the more involved upper extremity with this patient as noted by improvements in shoulder measurements and bimanual dexterity testing. These data are consistent with those of Wolf and colleagues (2002), who used RTP in a CIT framework. In the current study, no constraint was used, but during RTP, the patient was supervised and instructed to use only the more affected upper extremity.

After using a combined approach with HM and RTP, the patient displayed improved upper-extremity function. AROM in the shoulder, forearm, wrist, and fingers increased by more than 35%. The greatest gains in AROM were seen in the wrist (-50° to 15°). After the intervention, she could use both arms to lift her toddler. In addition, the patient was able to perform slow and deliberate eating, writing, ironing, and sweeping using the right upper extremity. Although she could perform these newly learned functional tasks slowly, she reverted to abnormal patterns of movement when time demands were placed on her during the WMFT. This finding may explain why some of the tests on the WMFT increased in time. She did not show changes in the areas requiring grasp-and-release and fine motor control, such as lifting a can, pencil, or paper clip and folding a towel. She was initially unable to perform these items and was not expected to improve on these sections. Therefore, the RTP was focused primarily on distal control in relation to wrist stability and resultant grip. On the WMFT, the most substantial change was on lifting a (weighted) basket. She was

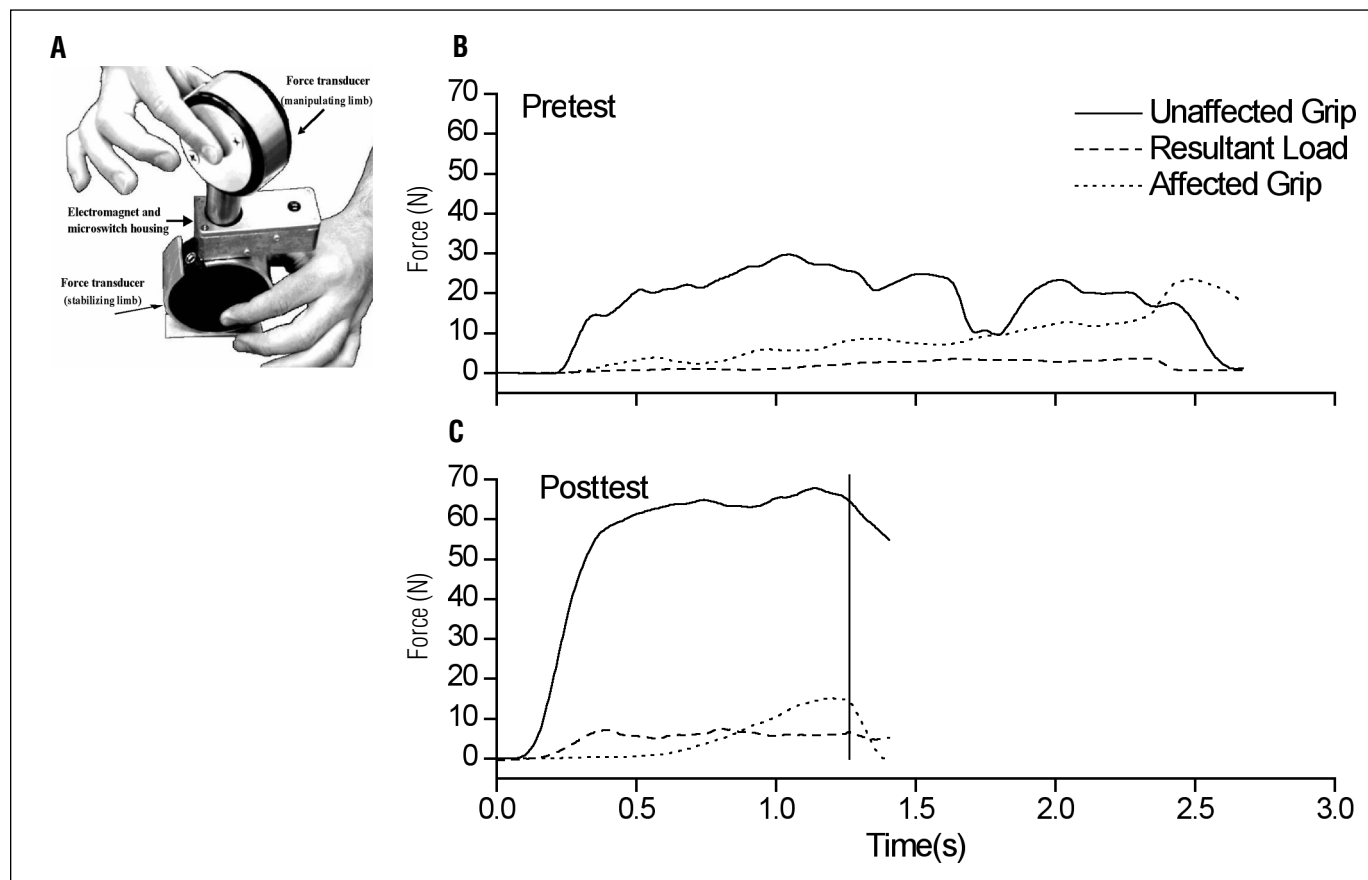


Figure 3. (A) Illustration of bimanual manipulation experimental device. The goal of the task is to remove the two transducers using precision grip for both hands. (B–C) Representative grip and pulling forces produced by the unaffected (solid line) and affected (dotted line) hands during the bimanual dexterity task. (B) Preintervention. (C) Postintervention. The patient was unable to perform the task before the intervention. In the posttest, however, she was able to produce sufficient grip and pulling forces with appropriate timing to separate the two objects. Object separation time is represented by the solid vertical line.

Note. N = Newtons.

initially unable to perform this task, but at the end of intervention, she was able to perform it in 8 s. This finding indicated that she had increased proximal control as well as distal control for wrist extension and finger flexion.

The Modified Ashworth Scale did not show changes in the wrist. We know that this test assesses spasticity by means of a quick stretch response. Spasticity is velocity dependent. Although the score did not change for wrist spasticity, the patient was able to control her wrist flexor tone as displayed by the ability to extend the wrist slowly and maintain at least neutral wrist extension and stability during functional tasks. The patient also was able to inhibit her strong tendency toward wrist flexion.

The contribution of the HM to improved upper-extremity performance cannot be determined precisely because this patient underwent a combined intervention. It appears that the repetitive nature of the HM and its focus on wrist and finger extension may be responsible for improved upper-extremity function and bimanual dexterity. The HM concentrates the patient's efforts distally. When initiating movement distally, after stabilizing proximally, she was able to isolate and vary movements throughout the upper extremity rather than using synergistic patterns that occurred when initiating all movement proximally.

An example of improved motor sequencing was observed in the bimanual dexterity task. Before the intervention, the patient had difficulty initiating and controlling digit forces. After the intervention, her pattern of grasping force initiation became more simultaneous, and she was able to generate grip and load (e.g., pulling) forces simultaneously. The simultaneous generation of grip and load forces allowed her to successfully perform the task. Although the preintervention force–time profiles are somewhat irregular with multiple peaks, the posttest data are relatively smooth for each force. Therefore, use of the HM in conjunction with RTP may improve the accuracy and specification of grasping forces.

One limitation of the current report is that the individual effects of the HM and RTP cannot be determined because this was a single case report. Additional patients are needed to determine the cause and effects of HM and RTP. It is possible that participation in RTP alone would have yielded the same results and the HM did not contribute to the improvement in function. However, it should be noted that this patient would not have been enrolled into a CIT program under the EXCITE inclusion criteria.

The findings in this case report were encouraging because the patient had a low level of function that would not qualify for CIT or other similar interventions. Moreover, the time spent in RTP with a therapist was reduced compared with a typical CIT intervention. The HM is simple

enough that it could be used in the home environment, which could further reduce patient need for direct therapist intervention. Finally, use of the HM with patients who have higher levels of upper-extremity function could allow therapists to focus efforts on functional activities in patients with stroke. Although the optimal dosage and use of the HM in conjunction with RTP is unknown at this time, further studies are planned to examine effectiveness of this intervention in a larger patient population. ▲

Acknowledgments

This work was supported by National Institutes of Health Grant R21-HD045514-01.

References

- Alberts, J. L., Butler, A. J., & Wolf, S. L. (2004). The effects of constraint-induced therapy on precision grip: A preliminary study. *Neurorehabilitation and Neural Repair*, 18, 250–258.
- Alberts, J. L., Tresilian, J. R., & Stelmach, G. E. (1998). The coordination and phasing of a bilateral prehension task. The influence of Parkinson's disease. *Brain*, 121, 725–742.
- Burgar, C. G., Lum, P. S., Shor, P. C., & Machiel Van der Loos, H. F. (2000). Development of robots for rehabilitation therapy: The Palo Alto VA/Stanford experience. *Journal of Rehabilitation Research and Development*, 37, 663–673.
- Finley, M. A., Fasoli, S. E., Dipietro, L., Ohlhoff, J., MacClellan, L., Meister, C., et al. (2005). Short duration robotic therapy in stroke patients with severe upper-limb motor impairment. *Journal of Rehabilitation Research and Development*, 42, 683–692.
- Flinn, S. R., & Ventura, D. (1997). *The Flinn Performance Screening Tool*. Columbus, OH: Functional Visions Incorporated.
- Fugl-Meyer, A. R., Jaasko, L., Leyman, I., Olsson, S., & Steglind, S. (1975). The post-stroke hemiplegic patient. *Scandinavian Journal of Rehabilitation Medicine*, 7, 13–31.
- Gregson, J. M., Leathley, M., Moore, A. P., Sharma, A. K., Smith, T. L., & Watkins, B. A. (1999). Reliability of the Tone Assessment Scale and the Modified Ashworth Scale as clinical tools for assessing poststroke spasticity. *Archives of Physical Medicine and Rehabilitation*, 80, 1013–1016.
- Johanson, M. E., & Murray, W. M. (2002). The unoperated hand: The role of passive forces in hand function after tetraplegia. *Hand Clinics*, 18, 391–398.
- Levine, P., & Page, S. J. (2004). Modified constraint-induced therapy: A promising restorative outpatient therapy. *Topics in Stroke Rehabilitation*, 11, 1–10.
- Morris, D. M., Uswatte, G., Crago, J. E., Cook, E. W., & Taub, E. (2001). The reliability of the Wolf Motor Function Test for assessing upper extremity function after stroke. *Archives of Physical Medicine and Rehabilitation*, 82, 750–755.
- O'Driscoll, S. W., Horii, E., Ness, R., Cahalan, T. D., Richards, R. R., & An, K. N. (1992). The relationship between wrist positions, grasp, size, and grip strength. *Journal of Hand Surgery*, 17, 169–177.

- Saling, M., Stelmach, G. E., Mescheriakov, S., & Berger, M. (1996). Prehension with trunk assisted reaching. *Behavioral Brain Research*, 80, 153–160.
- van der Lee, J. H., Wagenaar, R. C., Lankhorst, G. J., Vogelaar, T. W., Deville, W. L., & Bouter, L. M. (1999). Forced use of the upper extremity in chronic stroke patients. *Stroke*, 30, 2369–2375.
- Van Peppen, R. P. S., Kwakkel, G., Wood-Dauphinee, S., Hendricks, H. J. M., Van der Wees, P. J., & Dekker, J. (2004). The impact of physical therapy on functional outcomes after stroke: What's the evidence? *Clinical Rehabilitation*, 18, 833–862.
- Winstein, C. J., Rose, D. K., Tan, S. M., Lewthwaite, R., Chui, H. C., & Azen, S. P. (2004). A randomized controlled comparison of upper-extremity rehabilitation strategies in acute stroke: A pilot study of immediate and long-term outcomes. *Archives of Physical Medicine and Rehabilitation*, 85, 620–628.
- Wolf, S. L., Blanton, S., Baer, H., Breshears, J., & Butler, A. J. (2002). Repetitive task practice: A critical review of constraint-induced movement therapy in stroke. *Neurologist*, 8, 325–338.
- Wolf, S. L., Catlin, P. A., Ellis, M., Archer, A. L., Morgan, B., & Piacentino, A. (2001). Assessing Wolf Motor Function Test as outcome measure for research in patients after stroke. *Stroke*, 32, 1635–1639.
- Wolf, S. L., Thompson, P. A., Morris, D. M., Rose, D. K., Winstein, C. J., Taub, E., et al. (2005). The EXCITE trial: Attributes of the Wolf Motor Function Test in patients with subacute stroke. *Neurorehabilitation and Neural Repair*, 19, 194–205.
- Wolf, S. L., Winstein, C. J., Miller, J. P., Taub, E., Uswatte, G., Morris, D., et al. (2006). Effect of constraint-induced movement therapy on upper extremity function 3 to 9 months after stroke. *Journal of the American Medical Association*, 296, 2095–2104.

Best-Seller!

AOTA's Self-Paced Clinical Course

The Hand

An Interactive Study for Therapists

By Judy Colditz, OTR/L, CHT, FAOTA



This SPCC combines written coursework with interactive computer-based learning and examines the anatomical basis and clinical presentation of problems in the hand and forearm. Using the CD-ROM, *The Interactive Hand: Therapy Edition*, you will explore the multiple layers of complex anatomy while learning about palpation, examination, and the resource of common hand disorders.

This course also is an excellent preparation tool for the Hand Therapy Certification Exam.

Earn 1.6 AOTA CEUs (16 NBCOT PDUs / 16 contact hours).

Order #3017-J (with CD-ROM)

AOTA members: \$260 Nonmembers: \$360

SP-106



Call 877-404-AOTA ■ Shop online www.aota.org (Books & Products)